The Cranial Nerve Connection

Leonid Skorin, Jr., OD, DO, MS, FAAO, FAOCO

Consultant, Department of Surgery
Community Division of Ophthalmology
Mayo Clinic Health System in Albert Lea

Assistant Professor Ophthalmology
Mayo Clinic College of Medicine

Cranial Nerve 1 – Olfactory Nerve

1. Testing – patient shuts eyes
   - Examiner occludes one nostril
   - Test each nostril separately
   - Identify coffee, tobacco, peppermint, vanilla
   - Do not test noxious odors such as ammonia
   - Function of mucous membranes of nose NOT olfactory nerve
   - Unreliable test - Rarely performed

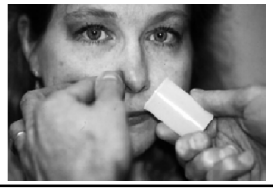

Cranial Nerve 1 – Olfactory Nerve

2. Results
   - Anosmia – loss of sense of smell
   - Bilateral loss – aging
   - Unilateral loss – trauma to cribriform plate
     a. blocked nasal passages
     b. Foster-Kennedy syndrome
        1) anosmia
        2) dementia
        3) unilateral optic atrophy
        4) contralateral disc edema
        5) etiology: subfrontal mass (olfactory groove meningioma)

Cranial Nerve 1 – Olfactory Nerve

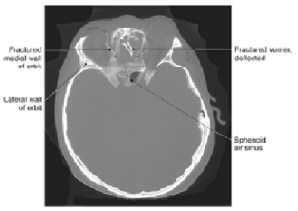

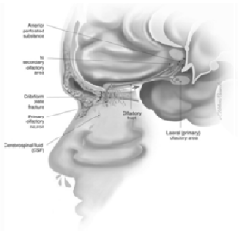

Cranial Nerve 2 – Optic Nerve

1. Testing
   - Visual acuity
   - Visual fields
   - Color vision
   - Pupil testing
     a) direct light reflex
     b) consensual light reflex
     c) swinging flashlight test
     d) near reflex



Cranial Nerve 2 – Optic Nerve

- 64 y.o. WF, optic nerve edema LT
- Blurred vision, grey inferior VF, LT
- Negative medical Hx, nonsmoker
- Family Hx: CVA, HTN, fatal valvular heart dz
- $20/20^{-1}$ RT, $20/40^{+2}$ LT
- 0.3 log units LT RAPD
- Red color saturation equal
- External/SLE negative
- BP: 158/95 mm Hg
- All blood test negative except cholesterol: 240 mg/dL, HDL 73 mg/dL

Cranial Nerve 2 – Optic Nerve

- Fundus: crowded discs, LT superior sectoral edema, blurred superior disc margins
- OCT: superior nerve fiber swelling LT

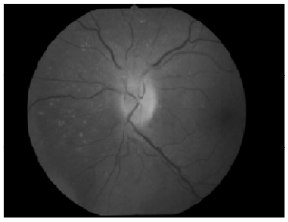

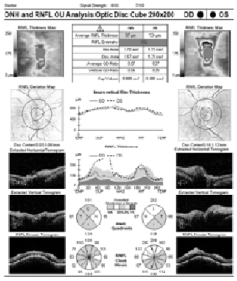

Cranial Nerve 2 – Optic Nerve

- VF: absolute infranasal altitudinal defect
- CT of head/orbit: negative

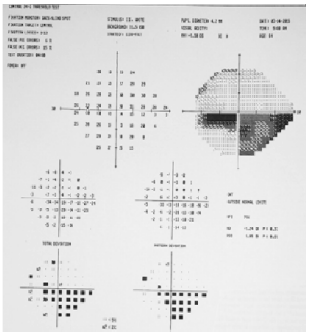

Cranial Nerve 2 – Optic Nerve

- Seen by internist 1 week later
- BP: 132/82
- Rx: 81 mg ASA daily
- Carotid US – no stenosis
- Seen again at eye clinic 5 weeks later
- RAPD and VF same
- BP: 140/82
- Fundus sectoral edema: mostly resolved

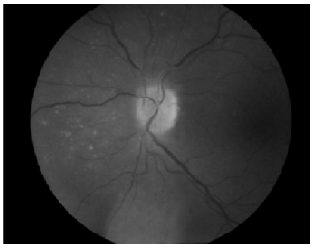

Cranial Nerve 2 – Optic Nerve

- NAION: acute, unilateral, painless vision loss
- Older than 50 years, Caucasian
- Disc at risk
- Inferior altitudinal VF defect
- Risk factors:
  a) hypertension
  b) nocturnal hypotension
  c) hyperlipidemia
  d) diabetes
  e) obstructive sleep apnea
  f) smoking
  g) PDE-5 inhibitor use (Viagra, Cialis, Levitra)

Cranial Nerve 2 – Optic Nerve

- White coat HTN: in-office BP > 140/90
- Masked HTN: in-office BP < 140/90 but elevated at home
- Increased risk of developing sustained HTN over 10 years
- Additional family hx:
  a) all siblings have HTN
  b) one had NAION
  c) one had CRAO

Hypertension definition Joint National Committee 7

- JNC7 defines normal blood pressure as <120/<80 mmHg
- Pre-hypertension: 120-139 systolic or 80-89 mmHg diastolic
- Hypertension:
  - Stage 1: 140-159/90-99 mmHg
  - Stage 2: ≥160 systolic or diastolic ≥100 mmHg

Requires screening measurement and average of two follow up measurements

Joint National Committee 8

- Did not address HTN definitions…..pre-HTN, stage 1, 2 etc….
- Focus now on <u>goals:</u>
  - ≥60 years old – treat if BP ≥ 150/90
  - <60 years old – treat if BP ≥ 140/90
  - DM or CKD – treat if BP ≥ 140/90

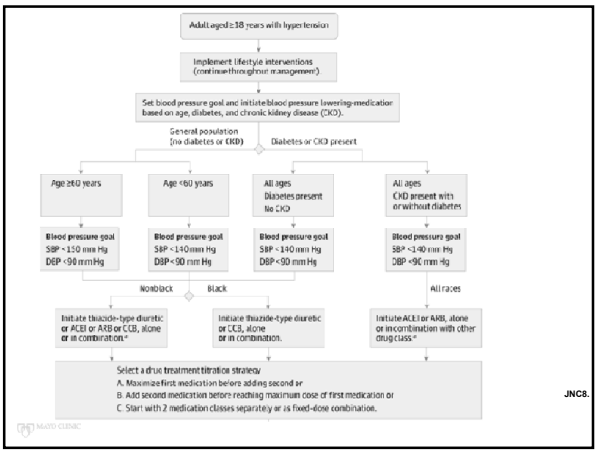

JNC8.

Cranial Nerve 3 – Oculomotor Nerve

1. Testing
   - A. Somatic motor controls
     - Superior, inferior, medial rectus muscles
     - Inferior oblique muscle
     - Levator palpebrae superioris muscle
   - B. Parasympathetic motor
     - Innervates fibers that control ciliary body and iris sphincter

Cranial Nerve 3 – Oculomotor Nerve

2. Results
   - Hypodeviated and exotropic "down and out"
   - Ptosis
   - Difficulty accommodating

Cranial Nerve 3 – Oculomotor Nerve

2. Results
   - Pupil dilation
     - a. benign ischemic infarction
     - b. compression from enlarging aneurysm at the junction of the carotid and posterior communicating arteries

Cranial Nerve 3 – Oculomotor Nerve

- 65 y.o. WF – acute, RT lid ptosis, binocular diplopia
- Dull pain behind RT eye and upper lid
- Diabetic Type II, HTN, hyperlipidemia, hypothyroid
- VA: $20/20^{-1}$ RT, 20/15 LT
- Pupil normal, no RAPD
- Motility – down and out with ptosis

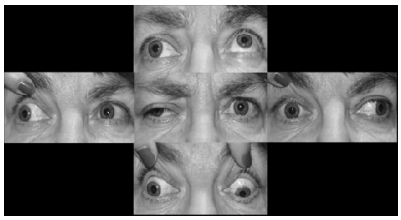

Cranial Nerve 3 – Oculomotor Nerve

- VF, color testing, sinus transillumination, SLE, fundus all normal
- HbA1C 6.2%, BS 103, CRP 10 mg/L, BP 139/71
- ICE test – negative
- Temporal artery biopsy – negative
- MRI and MRA of brain - negative

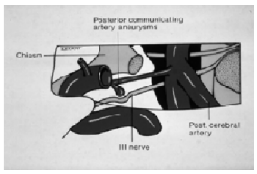

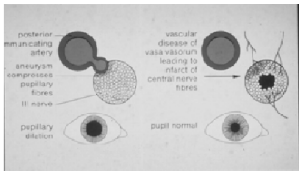

MAYO CLINIC

Cranial Nerve 3 – Oculomotor Nerve

- Microvascular ischemic 3rd nerve palsy
- Our patient had multiple risk factors
- Periorbital pain common – due to hypoxia
- Resolves in 8 – 12 weeks
- Always monitor for later pupil involvement

MAYO CLINIC

Cranial Nerve 4 – Trochlear Nerve

1. Testing
   - A. Somatic control
     - Controls superior oblique muscle
       - Parks-Bielschowsky 3-Step Test
       - double Maddox rod test for cyclodeviation
       - Maddox Wing
   - B. Results
     - Diplopia – vertical, diagonal or incyclotorsional, worse when reading
     - Head tilt to opposite side
     - Hyperdeviation worse on contralateral gaze, down gaze and ipsilateral head tilt

MAYO CLINIC

Cranial Nerve 4 – Trochlear Nerve

On Straight Gaze: hyperdeviation of right eye
On Adduction & Upgaze: overaction of I.O.
On Adduction and Depression: underaction of S.O.
Head Tilt to the Opposite Side

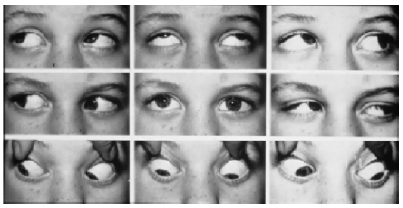

Cranial Nerve 4 – Trochlear Nerve

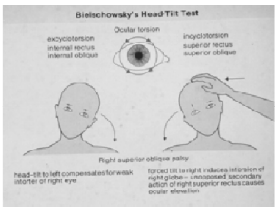

MAYO CLINIC

Cranial Nerve 5 – Trigeminal Nerve

- Sensory – light touch, pain, pressure, temperature
- Corneal reflex test – sensory 5 & motor 7 lid closure
- Ophthalmic, Maxillary, Mandibular
- Orbital floor blowout fracture: infraorbital nerve hypesthesia or anesthesia of ipsilateral cheek and upper lip

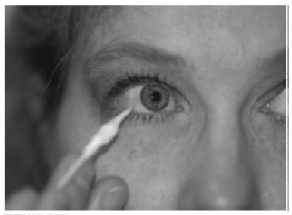

MAYO CLINIC

Cranial Nerve 5 – Trigeminal Nerve

- Motor – temporal, masseter, pterygoid muscles
- Jaw deviates toward side of weakness

Cranial Nerve 5 – Trigeminal Nerve

1. Herpetic neuralgia
   - Pain is severe, burning, aching
   - Pain precedes rash by 4 – 7 days
   - Distribution of dermatome (HZO)
   - Pseudodentrites, iridocyclitis
   - Hutchinson's sign – nasociliary branch
   - Pain regresses 1 – 2 weeks
   - Post-herpetic neuralgia – persists months to years

Cranial Nerve 5 – Trigeminal Nerve

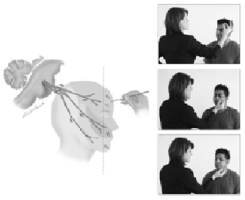

Cranial Nerve 5 – Trigeminal Nerve

- 50 y.o. WM pain behind RT eye
- Pain in RT temple and periocular region
- Mild blurring right eye
- Denies migraines or cluster headaches
- VA 20/20 RT/LT
- Pupils: 1mm anisocoria in light, ↑ to 2mm dark
- Pupils: no RAPD
- 3mm ptosis RUL

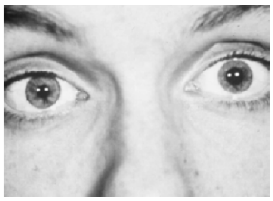

Cranial Nerve 5 – Trigeminal Nerve

- MRI/MRA/carotid US/CXR – negative
- 1% phenylephrine – reduced ptosis by 2mm and dilated pupil by 2mm; denervation hypersensitivity. 71% sensitive to 1% NS. Normal pupil does not dilate. Substitute for hydroxyamphetamine 1%.
- Confirms post-ganglionic (third order) Horner's
- Dx – Raeder's paratrigeminal neuralgia: 5th C.N. pain distribution with Horner's syndrome
- Tx – gabapentin, tegretol, baclofen

Cranial Nerve 6 – Abducens Nerve

1. Testing
   A. Somatic motor
      - Controls lateral rectus muscle
2. Results
   A. Diplopia – worse when looking laterally at distance

Cranial Nerve 6 – Abducens Nerve

3. Work-up and management (Nerves 3, 4, 6)

A. Patients under 50
- MRI/MRA
- Blood tests (FBS, ANA, RPR, Lyme titer, ESR)
- Lumbar puncture

B. Patients over 50
- Atherosclerosis evaluation
- ESR, CRP, platelets for temporal arteritis
- Consider MRI/MRA

C. Don't forget
- Myasthenia gravis
- Thyroid ophthalmopathy

Cranial Nerve 6 – Abducens Nerve

- 78 y.o. WF: acute horizontal diplopia
- Vague Hx of episode of amaurosis fugax
- Generalized weakness, unintentional weight loss
- New onset diffuse headache
- Well controlled hypertension
- VA: 20/20 RT/LT
- Pupils normal, no RAPD
- Motility – RT lateral rectus palsy

Cranial Nerve 6 – Abducens Nerve

- CBC – mild anemia 11.6 (14gms/dL)
- ESR – 61mm/hr ($\frac{[age+10]}{2} = \frac{78+10}{2} = \frac{88}{2} = 44$)
- CRP – 8mg/dL (<2.45)
- Platelets – 450,000 (150-450)
- Temporal artery biopsy - positive

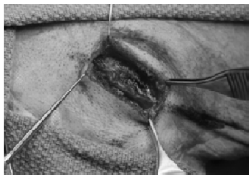

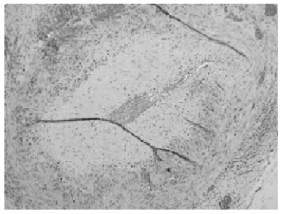

Cranial Nerve 7 – Facial Nerve

- Sensory – taste to anterior 2/3 tongue
- Motor – muscles of facial expression

Stroke vs. Bell's Palsy

- Upper motor neuron lesion
- Contralateral loss of lower muscle function
- Spares the forehead

Bell's Palsy vs. Stroke

- Lower motor neuron lesion
- Affects one entire side of face
- Ipsilateral to the lesion

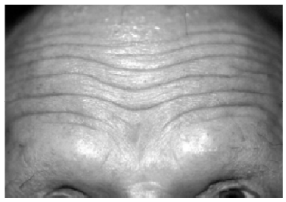

Cranial Nerve 8 – Acoustic Nerve

- Auditory acuity
- Sensorineural vs conduction deafness
- Weber test – lateralization
- Rinne test – compare air and bone conduction

Cranial Nerve 8 – Acoustic Nerve

- All sensory no motor function
- Weber Test – tuning fork: vertex of head
  - if normal, equal both sides
  - neurosensory loss, best in normal ear
  - conduction loss, best in abnormal ear
- Rinne Test - tuning fork: mastoid process
  - normally, air transmission greater than bone conduction
  - neurosensory loss, air greater than bone
  - conduction loss, bone greater than air

Cranial Nerves 7 and 8

- 85 y.o. WF: recent onset facial muscle spasms
- Periodic RT lid closing, elevation RT side of mouth
- Started 3 months ago, occurs 1-5 times daily
- RT ear feels full of water
- Past history of vertigo, RT sided hearing loss
- VA: 20/25 RT/LT
- Pupils normal, No RAPD
- No facial spasm seen

Cranial Nerve 7 – Facial Nerve

- Benign essential blepharospasm
  - bilateral contractions of orbicularis oculi, procerus and corrugator
  - idiopathic, benign, 50-70 years old
- Meige syndrome
  - BEB plus orofacial muscle contraction

Cranial Nerve 7 – Facial Nerve
(cont.)

- Hemifacial spasm
  - unilateral, intermittent facial muscle contractions
  - idiopathic, artery compressing 7th CN, aneurysm, multiple sclerosis, arteriovenous malformation, brainstem or cerebellopontine angle tumor
  - MRI to rule out brain pathology

Cranial Nerves 7 and 8

- MRI – 4x9 mm enhancing mass of RT internal auditory canal extending into RT cerebellopontine angle impinging Cranial Nerves 7 and 8

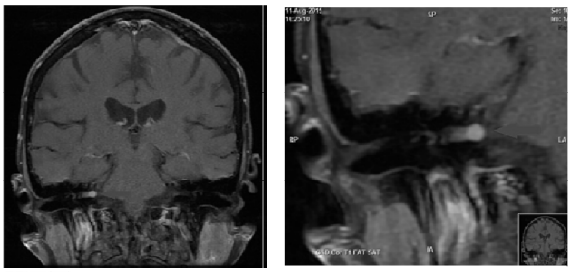

Cranial Nerves 7 and 8

- Audiogram – confirmed sensorineural hearing loss
- Vestibular schwannoma (acoustic neuroma)
- Benign, 80% of cerebellopontine angle tumors
- Surgery, radiation, botulinum toxin for facial spasms

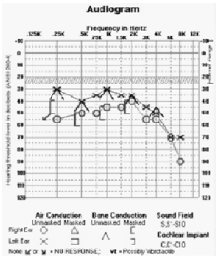

Cranial Nerve 9 – Glossopharyngeal Nerve

- Has sensory and motor fibers
- Innervates pharynx, posterior 1/3 tongue
- Gag reflex tests both CN 9 and CN 10 – Vagus
- Uvula deviates to unaffected side

Cranial Nerve 9 – Glossopharyngeal Nerve

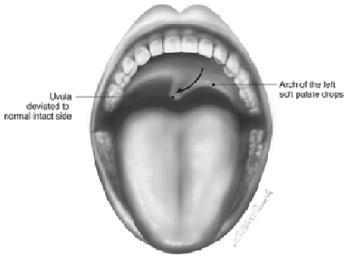

Cranial Nerve 11 – Accessory Nerve

- Motor – elevation and upward rotation of scapula
- Trapezius – shoulder shrug

Cranial Nerve 11 – Accessory Nerve

- Motor – tilts face and elevates chin to opposite side
- Sternocleidomastoid – palpate against resistance

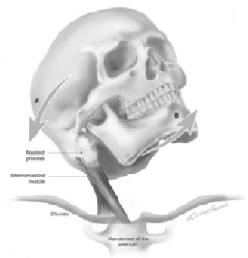

Cranial Nerve 12 – Hypoglossal Nerve

- Motor innervation to tongue
- Tongue deviates to side of weakness



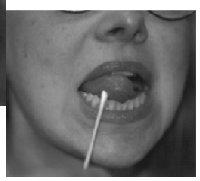

Cranial Nerve 12 – Hypoglossal Nerve

- Have patient stick out their tongue
  - normal: no deviation
  - abnormal: tongue deviates toward lesion

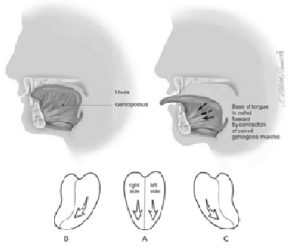

Motor System

- Gait: walk across room
- Cerebellar Disease: walk heel-to-toe (tandem gait)
- Romberg Test: patient stands with his feet together and with eyes closed. Tests for cerebellar ataxia. If Argyll-Robertson pupils present consider tabes dorsalis – syphilis.

Deep Tendon Reflex

- Knee reflex: with patient sitting, briskly tap the patellar tendon just below the patella
- Adie syndrome: tonic pupil & diminished deep tendon reflexes

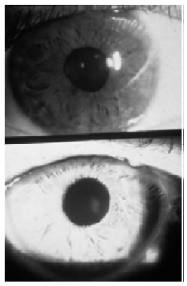

Adie Tonic Pupil

- Post-ganglionic denervation of iris sphincter and ciliary body
- No response to light, consensual absent
- Sluggish near response with slow redilation
- More neural fibers controlling near than pupillary reflex
- Light-near dissociation

Adie Tonic Pupil
(cont.)

- Vermiform pupil response – segmental constriction, sectoral iris sphincter palsy
- Young women, 80% - 90% unilateral, bilateral 4%/year
- Affected pupil slowly constricts over time becoming smaller than unaffected pupil
- Etiology – idiopathic, trauma, viral affects ciliary ganglion
- Denervation hypersensitivity – 1/8% pilocarpine – constricts Adie pupil

Thank You and Questions