

+



Anterior Segment Challenges

Marc R. Bloomenstein OD, FFAO
Schwartz Laser Eye Center
Scottsdale, AZ

+

Marc R. Bloomenstein OD, FFAO

- He is a regular everyday normal guy
- Who is an advisor for Alcon, Allergan, AMO, Bausch + Lomb, Tear Lab, EVI, OcuSoft
- Who has only \$600.00 in the bank and no financial interest in any products mentioned
- Who is the AOA CE Chairman, Past-President of the OCRT, Board Member of the OSSO, and retired dancer from [Thunder Down Under](#) (the Palm Beach, FL show) and enjoys walking on the beach, virgin pina-coladas and spooning.
- He has no financial interest in anything except:


+

Me Love STARBUCKS!

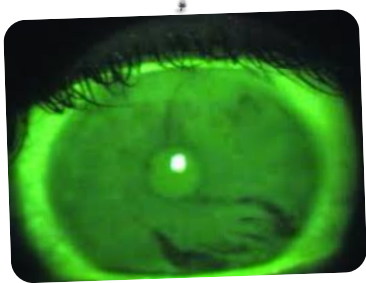


+

Lets Get Started



+ Ocular Surface

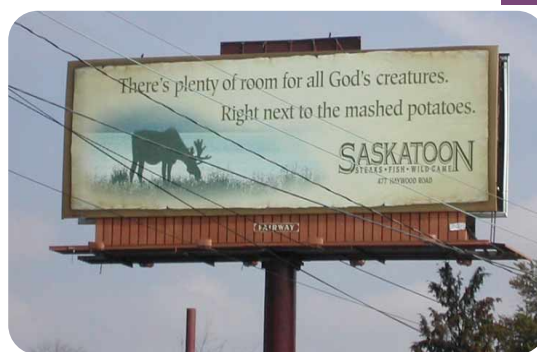

+ 59 Y.O spunky female

- * JB wears contact lenses
- * JB works in the airline industry
- * JB Chief Complaint
 - * "I am here to get new glasses and contacts. They dont seem to work as well as they used to."

+ What to do with JB

- * Treat the symptoms and prevent!
 - * Fluctuating Vision
 - * Contact Lenses
 - * Female
 - * Dry Eye? Ocular surface disease
 - * Treatment?



Case

+ 48 YO HF

- Diagnosed with POAG 1995
- Diagnosis made by ophthalmologist in Minnesota
- Relocated to Phoenix, I assume care
- Untreated peak IOP
 - OD=27mm Hg
 - OS=29mm Hg

+ 48 YO HF


Treatment History

- Initial therapy Timolol 0.5%
 - Discontinued after 2 months
 - Side effects of bradycardia & fatigue
- Current Medical Regimen:
 - Xalatan ou qPm x 2 yrs

+ 48 YO HF

- Since starting Xalatan IOP readings:
 - OD=17-19mm Hg
 - OS=18-20mm Hg
- Previous doctor felt that patient was being "safely" treated at this IOP level.

+ 48 YO HF
VF 2 yrs ago

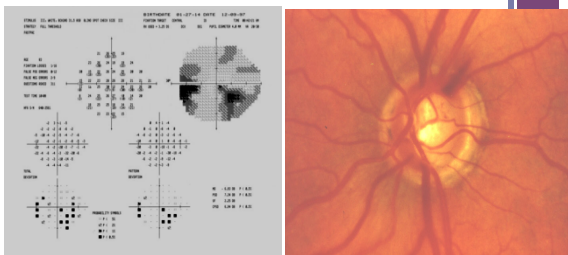


+ 48 YO HF
Initial Exam in Phoenix

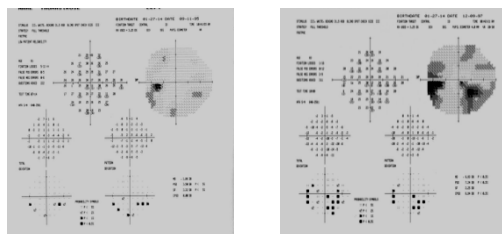
- BCVA 20/20 OU
- - RAPD
- IOP OD=17mm Hg OS=18mm Hg

- Subjectively, the patient
 - Reports excellent compliance
 - Denies any side-effects

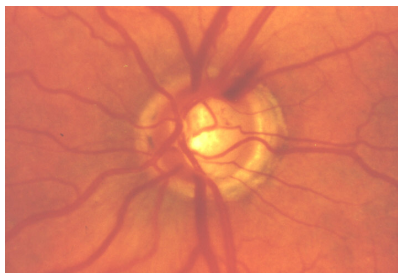
+ 48 YO HF
Left Eye: Phoenix ancillary tests



+ Visual Field Progression
in upper teens



*Disc hemorrhage suggests
Upper teens are NOT low enough*



+ Case

- 26 year old female “entertainer”
- Presented to office for a routine LASIK evaluation
- Wants LASIK to get rid of contacts that she has worn for 15 years
- “My left eye is bothering me”

+ Case

- BCVA
 - OD 20/20-2
 - OS 20/70
 - Slit lamp Exam
 - OD mild injection to conjunctiva
 - OS 1-2+ engorged vessels superiorly, with papillary reaction
- mild

+ Case

- Slit Lamp
 - OD- cornea had very faint yellow line superiorly
 - OS-yellow demarcation line with deposits superiorly
- Fundus OU was normal.

+



Cataract! The Band!

+

Case Study

- 65 year old sheila
 - "I need some new glasses. The ones I have are not strong enough"
 - LEE 1 year ago
 - PMHx: +HTN,
 - NKMA
- VACC
 - OD 20/30
 - Glare 20/400
 - OS 20/25
 - Glare 20/100

+

Thank You for attending...

MaeGruber